

Hyper eosinophilia, Hyper-IgE Syndrome, and Atopic Dermatitis in a Toddler With Food Hypersensitivity

E Estrada-Reyes,¹ MP Hernández-Román,¹ JD Gamboa-Marrufo,²
A Valencia-Herrera,³ AA Nava-Ocampo^{4,5}

¹Hospital Angeles Metropolitano, México DF, Mexico

²Departament of Internal Medicine, Hospital Infantil de México Federico Gómez, México DF, Mexico

³Service of Dermatology Hospital Infantil de México Federico Gómez, México DF, Mexico

⁴Divison of Clinical Pharmacology & Toxicology, Hospital for Sick Children, Toronto, Canada

⁵PharmaReasons, Toronto, Canada

■ Abstract

We describe a 20-month-old girl with hyper eosinophilia, hyper-immunoglobulin (Ig) E syndrome, and atopic dermatitis. Her peripheral eosinophil count and IgE plasma levels were $2.65 \times 10^9/L$ and 6702 IU/mL, respectively. Specific IgE levels for a variety of foods and inhalants were high and single-blind food challenges were positive for cow's milk, hen's egg, oat, wheat, and soy. When the patient received an extensively hydrolyzed milk formula, an exclusion diet, and 2 mg/kg of prednisone daily, the atopic dermatitis partially improved. Further improvement was observed with 1 mg/kg of azathioprine daily. Long-term clinical response was satisfactory. We suggest that food hypersensitivity should be ruled out in patients with hyper eosinophilia, hyper-IgE syndrome, and atopic dermatitis. Azathioprine may be a good therapeutic alternative for treatment in such cases.

Key words: Atopic dermatitis. Food allergy. Hyper eosinophilia. Hyper-IgE syndrome. Immunological diagnosis.

■ Resumen

Este es el caso de una niña de 20 meses de edad con hipereosinofilia, hiper-IgE y dermatitis atópica. Sus niveles periféricos de eosinófilos e IgE fueron $2.65 \times 10^9 /L$ y 6702 IU/mL, respectivamente. Las IgE específicas para una variedad de alimentos y aeroalérgenos fueron positivas, y la prueba de provocación simple ciego con alimentos resultó positiva con leche de vaca, huevo, avena, trigo y soja. La paciente recibió una fórmula extensamente hidrolizada, dieta de exclusión, y prednisona 2 mg/kg por día. Debido a que la dermatitis atópica sólo mejoró en forma parcial, se agregó al tratamiento azatioprina 1 mg/kg por día. La niña tuvo una respuesta clínica satisfactoria a largo plazo. En conclusión, se debería descartar una hipersensibilidad a los alimentos en los pacientes con hipereosinofilia, hiper IgE y dermatitis atópica; la azatioprina puede ser una buena alternativa terapéutica para tratar estos casos.

Palabras clave: Dermatitis atópica. Alergia a alimentos. Hipereosinofilia. Síndrome de hiper-IgE. Diagnóstico inmunológico.

Introduction

Hyper-immunoglobulin (Ig) E syndrome is a rare, complex immunoregulatory disorder characterized by hyperglobulinemia E, recurrent bacterial infections and chronic eczematoid dermatitis. The onset of this syndrome may occur at any time from early childhood onward, and may include severe eosinophilia and osteoarticular and dental abnormalities [1,2]. Food allergies represent a major problem in infants and children, and clinically-relevant food allergies are reported

in 40% to 60% of children with atopic dermatitis [3,4]. Both hyper-IgE syndrome and food allergies may result in an early onset of skin rash, eosinophilia and markedly elevated serum IgE levels. Occasionally, it may be difficult to distinguish between these disorders [5].

In this report, we describe the case of a toddler who had a combination of hyper eosinophilia, markedly elevated IgE levels, food allergy, and atopic dermatitis in order to illustrate the difficulty of establishing the diagnosis and initiating treatment promptly.

Case Description

The patient was a 20-month-old girl with no family history of atopy. She was delivered uneventfully at 40 weeks of gestation, with a body weight of 3 kg. Her Apgar score was 9 at 1 minute and 9 at 5 minutes after birth. She was exclusively breastfed until the age of 4 months. Physical examination on day 3 after birth revealed an oozing, crusted rash on the face and scalp and a generalized maculopapular and papulovesicular rash on her face, scalp, back, neck, chest, and abdomen. The patient was diagnosed with atopic dermatitis and her skin lesions were unresponsive to a variety of oral antihistamines and hydrocortisone creams.

The patient was referred to the Hospital Infantil de México Federico Gómez at the age of 20 months. Growth retardation was evident (weight and length had fallen from the 90th percentile at birth to below the 5th percentile at the age of 20 months). During the examination, we observed clear signs of atopic dermatitis, including oozing, scratching, and erythema with excoriations (Figure). Her peripheral eosinophil count was $2.65 \times 10^9/L$; IgE level, 1548.5 IU/mL; platelet count, $672 \times 10^9/L$; and hemoglobin level, 12.2 g/dL. She had a chronic middle ear infection, dental caries, chronic diarrhea, pneumonia, hepatosplenomegaly, lymphadenopathy, oral and esophageal candidiasis, and hypoalbuminemia (3.1 g/dL). A simple chest radiograph was reported as normal. Systemic parasitoses secondary to *Toxocara* species larvae, *Fasciola hepatica* and *Ascaris lumbricoides* were ruled out by microbiological analysis of stool or serology. Candidin and tuberculin skin tests were negative.

Her serum immunoglobulin titers were IgG, 1060 mg/dL; IgA, 69.9 mg/dL; and IgM, 62.4 mg/dL. A test for isohemagglutinin IgM anti-B was positive 1/16. Flow cytometry of peripheral blood to analyze lymphocyte subpopulations showed the following values: CD3, 48% (limits of normal, 39%-73%); CD4, 23% (normal, 25%-50%); CD8, 25% (normal, 11%-32%). The CD4/CD8 ratio was 0.9 (normal, 0.9-3.7) [6].

No malignant cells were found in the bone marrow aspirate. Chemiluminescence and nitroblue tetrazolium tests were normal. Liver biopsy showed normal histology. Skin biopsy of affected areas showed nonspecific inflammation and eosinophilic infiltration. Lymph node biopsy showed nonspecific inflammation. Her karyotype was normal. Esophageal biopsy identified mild esophagitis, gastritis, and duodenitis with eosinophilic infiltration.

Radioallergosorbent tests (ImmunoCAP, Pharmacia AB, Uppsala, Sweden) gave the following results: >300 IU/L for milk and >242 IU/L for chicken egg, *Dermatophagoides pteronyssinus*, *Dermatophagoides farinae*, *Cynodon dactylon*, *Phleum pratense*, soy, and wheat.

In accordance with European Academy of Allergology and Clinical Immunology recommendations [7], a single-blind food challenge was performed. Briefly, for a period of 2 weeks, the patient took a diet excluding suspected foods (cow's milk, chicken eggs, wheat, nuts, peanuts, soy, etc). The regimen was adequate for minimizing nutritional deficiency. The foods tested were egg, barley, lentils, milk, nuts, oat, peanuts, soy, tuna fish, cod fish, and wheat. Each different food was tested in a masked form every 48 hours. A total of 1 raw egg (white and

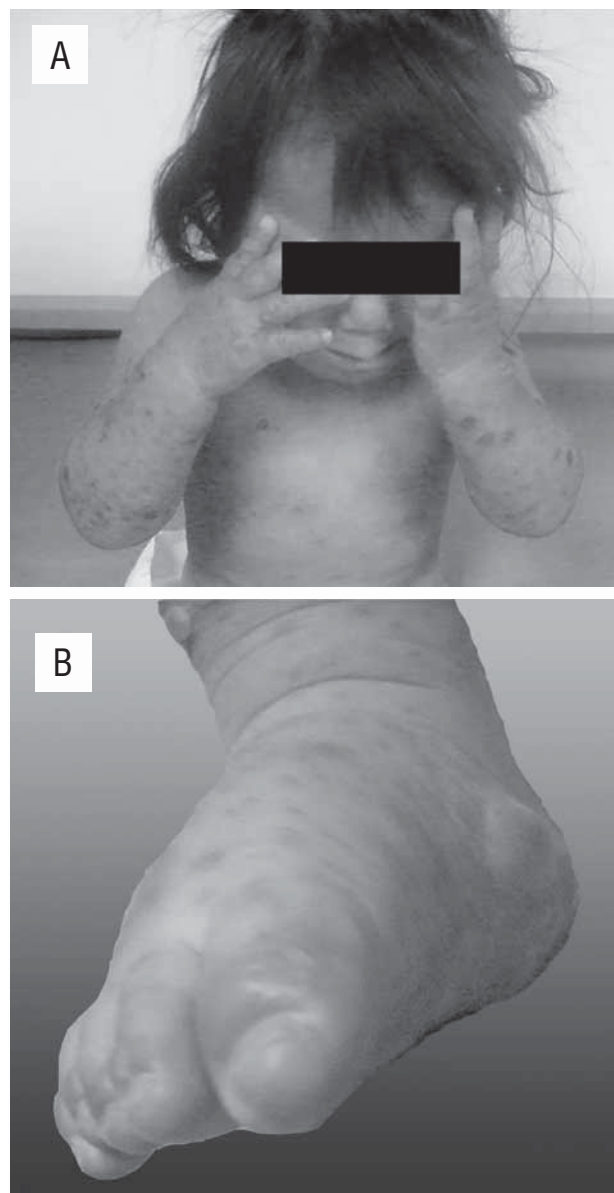


Figure. Atopic dermatitis in a 20-month-old girl with hyper-eosinophilia associated with hyper-immunoglobulin E syndrome, and food hypersensitivity. Skin lesions (oozing, scratching, and erythema with excoriations) were visible all over her body: face, arms and trunk (A) and legs and feet (B).

yolk) was given to the patient. Successive doses of 0.1, 0.3, 1, 3, 10, 30, and 100 mL of fresh pasteurized cow's milk containing 3.5% fat were tested. Wheat powder was dissolved in water and given in a similar dosage regimen until a total amount of 10 g of wheat protein had been provided. The time interval between doses was 30 minutes. Provocation was stopped if clinical symptoms were observed or after reaching the highest dose. Each food challenge was scored as positive if the tester observed objective clinical reactions, including urticaria, angioedema, wheezing, vomiting, diarrhea, abdominal pain, or exacerbation of eczema, resulting in a 10-point increment

in scores derived from the Scoring Atopic Dermatitis tool (SCORAD). Clinical reactions observed within 2 hours were defined as early reactions whereas those occurring later were classified as late reactions [8]. In our patient, single-blind food challenges gave positive results for cow's milk, egg, oat, wheat, and soy. The patient received an extensively hydrolyzed milk formula and a diet excluding milk, gluten cereals (wheat and oat), egg, and soy.

After approximately 2 months of dietary treatment, only partial remission of dermatitis had been achieved. Therefore, oral prednisone at a dosage of 2 mg/kg daily was added to the treatment. A month later, the girl had an eosinophil count of $0.13 \times 10^9/L$ and a platelet count of $458 \times 10^9/L$, respectively. However, she still had skin lesions. Prednisone was slowly tapered off and azathioprine was initiated at a dosage of 1 mg/kg daily.

After 11 months of treatment, the girl was completely asymptomatic, had an eosinophilic and platelet count of $0.74 \times 10^9/L$ and $447 \times 10^9/K$, respectively, and had no hepatosplenomegaly.

Discussion

This child underwent extensive clinical and laboratory examinations to establish an association between food hypersensitivity and the triad of hypereosinophilia, hyper-

Table 1. Examples of Causes of Hypereosinophilia and Hyper-IgE Syndrome

Hypereosinophilia ^a : $> 1.5 \times 10^9/L$	Hyper IgE ^b : 1875 up to 80 000 IU/mL
Parasitic diseases (eg, ascaris, filariasis, trichinosis)	Hyper-IgE syndrome
Infectious diseases, mainly associated with immunodeficiency syndrome	Wiskott-Aldrich syndrome
Drug hypersensitivity	Ommen syndrome
Inflammatory connective tissue diseases	Cornel-Netherton syndrome
Acute and chronic eosinophilic leukemia	
Idiopathic hypereosinophilic syndrome	

Abbreviation: IgE, immunoglobulin E.

^a Based on Spry [12]

^b Based on Grimbacher et al [2]

IgE syndrome and atopic dermatitis. Since the onset of dermatitis was at the age of 3 days, differential diagnosis of skin disorders in the newborn were considered, particularly Netherton syndrome, which is characterized by a triad of symptoms including congenital ichthyosiform erythroderma,

Table 2. Differential Diagnosis of Hypereosinophilia, Hyper-IgE Syndrome, Food Allergy, and Atopic Eczema

	Hypereosinophilia [16]	Hyper-IgE syndrome [2,5]	Food allergy [17-19]	Atopic eczema dermatitis syndrome [4]
Age of onset	5 months (based on 1 report)	Within a few days or weeks of life	From birth to 3 years	Early infancy
Gender predominance	Male-to-female ratio 9:1	No gender predominance	Male	No gender predominance
Prevalence	1:200 000	Incidence $< 10^{-6}$	0.1% to 7% of population	10% to 15% of the pediatric population
Systemic involvement	Cardiovascular, neurological, hematological, gastrointestinal, etc	Abscesses, pneumonia, mucocutaneous candidiasis, connective tissue abnormalities, impaired deciduation of primary teeth	Respiratory (asthma, rhinitis), gastrointestinal (vomiting, diarrhea and abdominal pain), anaphylaxis	Between 50% and 80% of children develop other atopic diseases such as allergic rhinitis and asthma
Skin involvement	Generally, either angioedematous and urticarial lesions, or erythematous, pruritic papules, and nodules	Rash usually begins on the face and/or scalp as pink to red papules that become pustules and then break down, exuding pus, and becoming crusted	Atopic dermatitis, dermatitis herpetiformis, gluten, milk and soy enteropathies, and eosinophilic gastroenteritis, urticaria, angioedema	Rash distribution varies with age, involving cheeks and external surfaces of the arms and legs in infancy
Prognosis	Depends on the severity of ultimate organ damage. Malignant blood disorders are a concern.	Benign if treatment is established early	About 80% of children with milk and egg allergy will outgrow it by the age of 5 y; 20% of peanut-allergic children will outgrow the allergy.	Approximately a third of children with AD and food allergy outgrow their clinical reactivity in 1-3 y.

Abbreviations: AD, atopic dermatitis; IgE, immunoglobulin E.

trichorrhix invaginata, and atopy. Netherton syndrome is associated with electrolyte disorders, food-induced anaphylaxis and prolinuria [9]. However, our patient did not show the characteristic clinical picture of Netherton syndrome.

There are 3 categories of peripheral eosinophilia: first, the reactive (nonclonal) eosinophilias observed in parasitic infestations, asthma or allergies; second, the clonal disorders of bone marrow; and third, idiopathic hypereosinophilic syndrome, in the absence of any clonal abnormality or reactive cause [10,11]. In the case we have described, most of the potential causes of hypereosinophilia (Table 1) were ruled out by the patient's clinical course, the negative laboratory results for parasitic infections, and the lack of immunodeficiency both in peripheral blood tests and the bone marrow biopsy.

Although eosinophilia may be present in patients with atopic dermatitis, in general, hypereosinophilia has rarely been reported [12]. We experienced difficulties in establishing our patient's diagnosis due to the fact that this toddler simultaneously had hypereosinophilia, hyper-IgE, and atopic dermatitis. Almost any parasitic invasion of tissues can elicit eosinophilia. Among neoplastic diseases, Hodgkin disease may elicit striking eosinophilia, whereas it is seen less often in non-Hodgkin lymphoma, chronic myelogenous leukemia, and acute lymphoblastic leukemia [10,11]. Acquired and congenital immune disorders, often with eczema, are frequently associated with eosinophilia. For example, Ommen syndrome is an autosomal recessive form of severe combined immunodeficiency (SCID) characterized by erythrodermia, desquamation, chronic diarrhea, failure to thrive, lymphadenopathy, and hepatosplenomegaly [13,14]. Patients may develop fungal, bacterial, and viral infections typical of SCID. These disorders were ruled out in our patient.

Hyper-IgE syndromes are characterized by the clinical triad of high serum levels of IgE (>2000 IU/mL), recurring staphylococcal skin abscesses, and pneumatocele formation. Most cases are sporadic, but both autosomal dominant and recessive forms have been described (Table 1). Skeletal symptoms such as joint hyperextensibility, scoliosis, osteoporosis, and retained primary teeth are associated with the autosomal dominant form, whereas the autosomal recessive disease is mainly characterized by severe recurrent viral infections. Severe eosinophilia and devastating neurological complications are often fatal in childhood. However, a mild form without skeletal or dental abnormalities has recently been described in Mexican patients [1,2]. Children producing IgE antibodies toward food allergens often also develop IgE antibodies against inhaled allergens [15]. The treatment of hyper-IgE syndrome was recently reviewed [16]. Our patient showed a good clinical response to treatment with azathioprine and remained asymptomatic during the 11 months of follow-up.

The prevalence of food allergies may vary from 0.3% to 7.5% and dairy products for infants that have high allergenic potential may be derived from different protein sources such as bovine casein, wheat, pork collagen, chicken egg and soy [3,17-19]. Both hyper-IgE syndrome and food allergies can result in the early onset of skin rash, eosinophilia and markedly elevated serum IgE. Occasionally, it can be difficult to distinguish these 2 disorders [5]. Patients with food

allergy may have gastrointestinal, respiratory or cutaneous symptoms [17], and they have frequent exacerbations of atopic dermatitis. In our patient, the immunosuppressive treatment with azathioprine and dietary restriction successfully controlled her dermatitis.

In conclusion, patients with hypereosinophilia, hyper-IgE syndrome, and atopic dermatitis should be evaluated for food hypersensitivity. To rule out the extensive list of disorders that may produce hypereosinophilia or a hyper-IgE syndrome may be costly and time-consuming in comparison to the prompt evaluation of the patient for food allergies (Table 2). Finally, azathioprine may be a good therapeutic alternative for treating cases with severe systemic complications of food hypersensitivity.

References

1. Shemer A, Weiss G, Confino Y, Trau H. The hyper-IgE syndrome. Two cases and review of the literature. *Int J Dermatol*. 2001;40:622-8.
2. Grimbacher B, Holland SM, Puck JM. Hyper-IgE syndromes. *Immunol Rev*. 2005;203:244-50.
3. Niggemann B, Beyer K. Diagnostic pitfalls in food allergy in children. *Allergy*. 2005;60:104-7.
4. Sampson H. Eczema and food hypersensitivity. In: Metcalfe DD, Sampson HA, Simon AR, editors. *Food allergy: adverse reactions to foods and food additives*. Oxford: Blackwell Science; 2003. p. 144-57.
5. Hernandez-Trujillo VP, Nguyen WT, Belleau JT, Jeng M, Conley ME, Lew DB. Cow's milk allergy in a patient with hyper-IgE syndrome. *Ann Allergy Asthma Immunol*. 2004;92:469-74.
6. Comans-Bitter WM, de Groot R, van den Beemd R, Neijens HJ, Hop WC, Groeneveld K, Hooijkaas H, van Dongen JJ. Immunophenotyping of blood lymphocytes in childhood. Reference values for lymphocyte subpopulations. *J Pediatr*. 1997;130:388-93.
7. Bindslev-Jensen C, Ballmer-Weber B, Bengtsson U, Blanco C, Ebner C, Hourihane J, Knulst CA, Moneret-Vautrin AD, Nekam H, Niggemann B, Osterballe B, Ortolani C, Ring J, Schnopp C, Werfel T. Standardization of food challenges in patients with immediate reactions to foods—position paper from the European Academy of Allergology and Clinical Immunology. *Allergy*. 2004;59: 690-7.
8. Niggemann B, Reibel S, Wahn U. The atopy patch test (APT): a useful tool for the diagnosis of food allergy in children with atopic dermatitis. *Allergy*. 2000;55:281-5.
9. Hausser I, Anton-Lamprecht I. Severe congenital generalized exfoliative erythroderma in newborns and infants: a possible sign of Netherton syndrome. *Pediatr Dermatol*. 1996;13: 183-99.
10. Brito-Babapulle F. The eosinophilias, including the idiopathic hypereosinophilic syndrome. *Br J Haematol*. 2003;121:203-23.
11. Fauci AS, Harley JB, Roberts WC, Ferrans VJ, Gralnick HR, Bjornson BH. NIH conference: The idiopathic hypereosinophilic syndrome. Clinical, pathophysiologic, and therapeutic considerations. *Ann Intern Med*. 1982;97:78-92.
12. Spry C. The hypereosinophilic syndrome: clinical features, laboratory findings and treatment. *Allergy*. 1982;37:539-51.

13. Buckley RH. Disorders of the IgE system. In: Stiehm RE, editor. Immunologic disorders in infants and children. 4th Edition. WB Saunders Co, Philadelphia; 1996. p. 409-22.
 14. Elder ME. T-Cell immunodeficiencies. *Pediatr Clin North Am*. 2000;47:1253-74.
 15. Niggemann B, Sielaff B, Beyer K, Binder C, Wahn U. Outcome of double-blind, placebo-controlled food challenge tests in 107 children with atopic dermatitis. *Clin Exp Allergy*. 1999;29:91-6.
 16. Roufosse F, Cogan E, Goldman M. Recent advances in pathogenesis and management of hypereosinophilic syndromes. *Allergy*. 2004;59:673-89.
 17. Bock SA. Prospective appraisal of complaints of adverse reactions to foods in children during the first 3 years of life. *Pediatrics*. 1987;79:683-8.
 18. Muraro A, Dreborg S, Halken S, Host A, Niggemann B, Aalberse R, Arshad SH, Berg Av A, Carlsen K, Duschek K, Eigenmann P, Hill D, Jones C, Mellon M, Oldeus G, Oranje A, Pascual C, Prescott S, Sampson H, Svartengren M, Vandenplas Y, Wahn U, Warner JA, Warner JO, Wickman M, Zeiger RS. Dietary prevention of allergic diseases in infants and small children. Part I: immunologic background and criteria for hypoallergenicity. *Pediatr Allergy Immunol*. 2004;15:103-11.
 19. Lever R. The role of food in atopic eczema. *J Am Acad Dermatol*. 2001;45:S57-60.
- *Manuscript received April 13, 2007; accepted for publication September 4, 2007.*
- **Elizabeth Estrada-Reyes**
- Consulta de Alergia Pediátrica
Torre Diamante, Apto. 300
Hospital Ángeles Metropolitano, Tlacotalpan N° 59
México DF 06760, México
E-mail: elizabeth.estrada-reyes@gmail.com